

The Epilatory Effects of Trypsin on Human Skin, Applied via Lecithin Reverse Micelles

E.E. Protopapa¹, A. Xenakis², S. Avramiotis², E.V. Prodromou³ and S.M. Koukaki³

¹ Technological Educational Institution of Athens, Athens, Greece

² Institute of Biological Research and Biotechnology, National Hellenic Research Foundation, Athens, Greece

³ Pharmathen Ltd, Athens, Greece

Key words Trypsin, epilatory effects, human skin, lecithin reverse micelles

Received for publication 15 November 1998

Accepted for publication 20 December 1998

S u m m a r y *A method of epilation using reverse micelles containing the proteolytic enzyme, trypsin, is described based on previous experimental findings on degenerative effects of proteolytic enzymes on hair follicles and follicle stem cells of guinea pigs and mice. The method involves rubbing of the preparation on wax epilated skin and leads to removal of hair from various skin regions, such as face, shoulders, arms and legs. The many advantages of this method renders it the method of choice for hair removal in cosmetology.*

INTRODUCTION

Proteolytic enzymes have been used as epilatory agents initially in the wool industry (1), later in relation to research on the mechanism of action of the enzymes on hair follicles and the epilatory process (2,3). In the last named studies, trypsin, chymotrypsin and papain have been applied on

wax epilated skin by iontophoresis, or, in the case of trypsin, also in form of reverse micelles, leading to a series of histopathological effects on hair follicles, explaining the epilatory results. In experiments with transgenic mice (4) carrying the lacZ gene linked to the upstream regulatory region of HPV11 expressing the gene specifically in cells of the bulge area (5) presumed to be the hair follicle stem cells (6), application of trypsin in form of reverse micelles (3) led, in addition to the degenerative effects on hair follicles, also to the presence of cells of the bulge area within the lumen, detached from that area, implying thus an impairment of the function of these putative stem cells (3). In the present study, trypsin in form of reverse micelles, has been applied as an epilatory agent on previously wax epilated skin of 500 volunteers and the effect of this treatment on hair regrowth was observed. The results led to the conclusion that trypsin application in form of reverse micelles can stop, or significantly impair, hair regrowth, rendering it suitable as an epilatory agent in skin cosmetology.

Send reprint requests to Dr E. Protopapa, Technological Educational Institution (TEI) of Athens, Ag Spyridonos, 122 43 Aigaleo, Athens, Greece

MATERIALS AND METHODS

Choice of volunteers

Five hundred volunteers have been chosen, for each one a protocol has been completed containing information on sex, age, area to be treated (e.g. face, shoulders, arms, legs), family history, previous treatments (razor, iontophoresis) and possible ailments (allergy, endocrine disorders).

Preparation of reverse micelles (3,7)

Lecithin forms microemulsions in isooctane in the presence of short chain alcohols. Stock solutions of 3-10% w/w lecithin in isooctane were prepared and kept under nitrogen. Solubilization was accomplished by stirring and occasionally by briefly heating at 40°C. Water content was checked by Karl Fischer titrations. The amount of water (usually less than 1%) was taken into consideration in the calculations of the total water content. Microemulsions were formed by adding the appropriate amounts of propanol and buffered stock trypsin solution (1 mg/ml). Solubilization was achieved within less than one minute by gentle shaking. The total amount of water was adjusted to give the desired value of the ratio $w_0 = (H_2O)/(lecithin)$.

Application of reverse micelles and evaluation of results

The preparation was applied by rubbing for two minutes on previously wax epilated skin. Rubbing was performed three times daily for three consecutive days. Evaluation was made 9 weeks afterwards and was based on the following criteria:

- Hair color modification,
- hair texture and type, and
- speed of hair regrowth.

The results were graded:


- excellent, no hair or minimal hair regrowth of fragile hair with color change,
- good, minimal hair regrowth of softer hair of lighter coloration,
- moderate, moderate regrowth of thinner hair with slightly lighter coloration, and
- poor, no difference to untreated skin.

Table 1
Distribution of treated areas

Treated areas	Count	Percentage (%)
Face	141	28.2
Shoulders	115	23
Arms	9	1.8
Legs	7	1.4
Face, Abdomen	66	13.2
Face, Arms, Legs	14	2.8
Face, Abdomen, Arms, Legs	46	9.2
Face, Shoulders	7	1.4
Legs, Arms	31	6.2
Face, Arms	28	5.6
Face, Abdomen, Arms	14	2.8
Abdomen, Arms, Legs	7	1.4
Face, Neck	2	0.4
Face, Abdomen Breast	2	0.4
Upper lip	9	1.8
Abdomen, Arms	2	0.4

RESULTS AND DISCUSSION

Five hundred persons, 368 women (73,6%) and 132 men (26,4%) suffering from excess hair growth on various parts of the body, were submitted to treatment with the liposome preparation containing trypsin, as described in Materials and Methods. Eighty five percent of these persons were in the age group of 15-35, the rest were over 35 years old. As shown in Table 1 and Figure 1, various areas were treated, 51% involved solely face or shoulders, a small proportion (5%) either arms, legs and upper lip, alone, and the rest various combinations (e.g. face-abdomen, face-abdomen-arms, etc). In this report we present results referring solely to the individual areas and not to the combination of areas, which together with data on some male-female particularities and effects of pathological disorders, will be reported in a forthcoming publication. As shown in Table 2 and Figure 2 the results of treatment of the face area were graded excellent in 93 cases (66%), good in 21 cases (14,8%), moderate in 20 cases (14,1%) and poor in 7 (5%). In the treatment of the shoulder area, the results were excellent in 45 cases (39,1%), good in 70 (60,9%), with no observed moderate or poor cases. In the case of treatment of the arms, all seven cases were graded excellent, whereas in the treatment of the legs, all seven cases were evaluated as good. The nine cases treated in the upper lip gave excellent results.



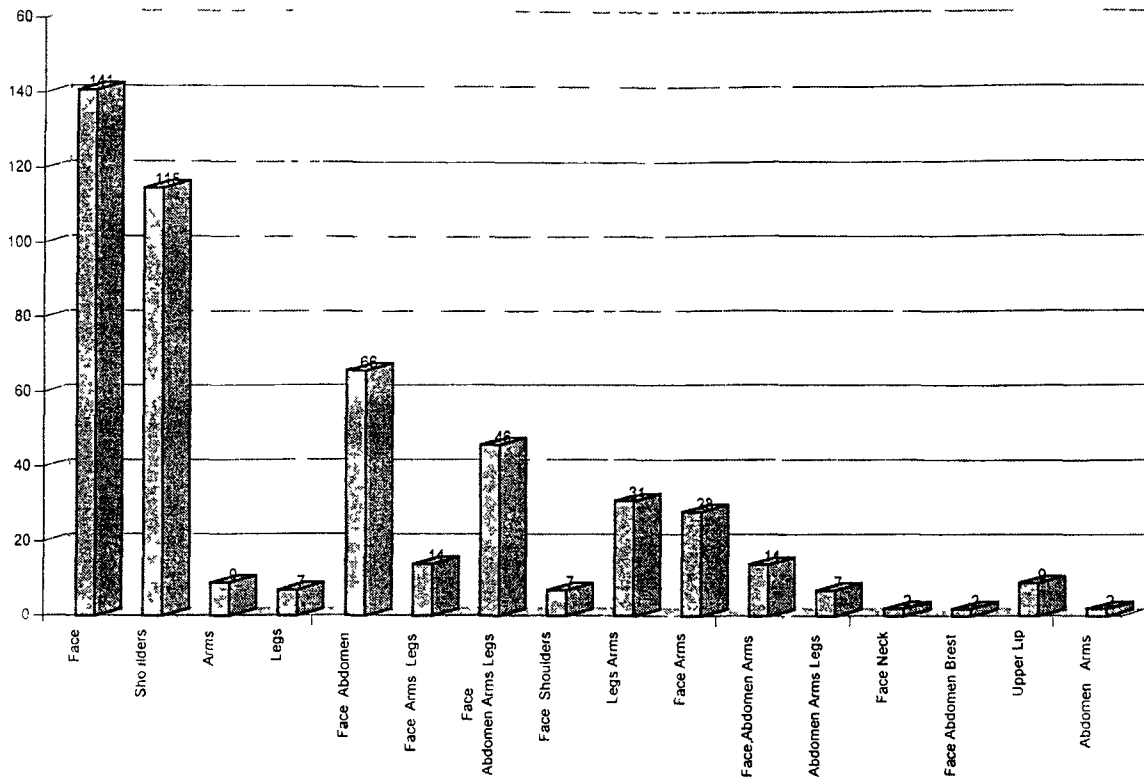


Figure 1 Distribution of treated areas

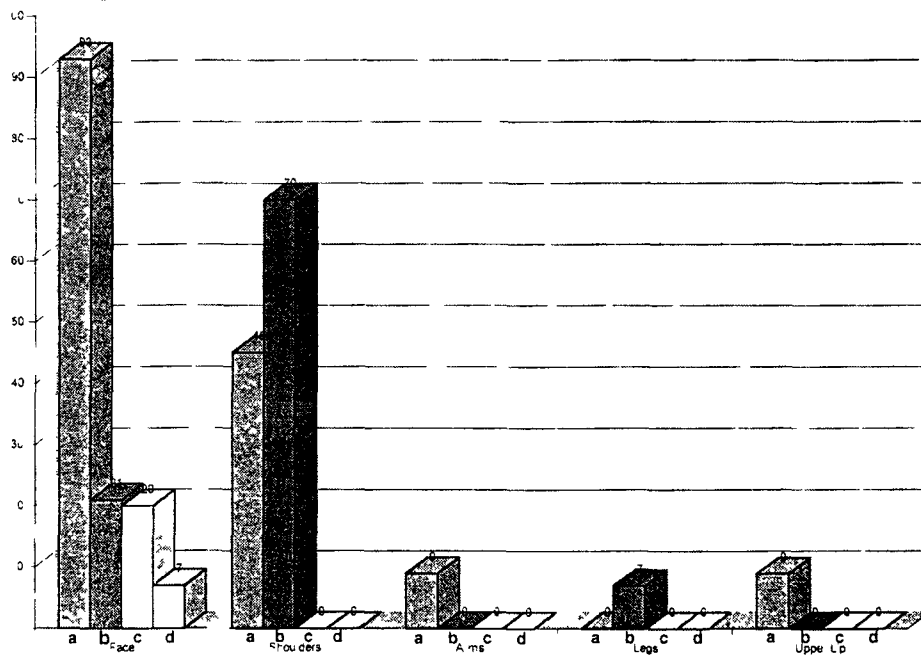


Figure 2 Evaluation of results according to areas treated
a Excellent b Good c Moderate d Poor

Table 2
Evaluation of results according to areas treated

Area	Excellent	Good	Moderate	Poor
Face	93	21	20	7
Shoulders	45	70	0	0
Arms	9	0	0	0
Legs	0	7	0	0
Upper lip	9	0	0	0

From the obtained results it is evident that the described epilatory procedure is suitable for treatment of excessive hair growth in various parts of the body, i.e. face, shoulders, arms and legs, but also of neck and abdomen (results to be presented). The results were graded excellent or good, with only a few moderate or poor ones, pertaining to treatment of face areas, most of which were previously excessively treated with conventional epilatory procedures. In some of these cases, repeating the reverse micelles treatment yielded excellent to good results (results to be presented).

The epilatory method described in this paper, based on experimental work with guinea pigs (2) and transgenic mice (3), showing degenerative effects of proteolytic enzymes on hair follicles and on the putative stem cells of the bulge area has a series of advantages over conventional epilatory techniques: it is simple (only rubbing of the preparation on the required area is necessary) and can be performed by the patient him(her)self after receiving the first instructions of the esthetician, it is painless, does not require any instrumentation, is

therefore inexpensive, and does not lead to skin damage.

The method therefore, has the prerequisites and advantages to be the method of first choice in hair epilation, the other known epilatory methods (such as needle, iontophoresis, etc.) to be used only in the few cases where the reverse micelles method has failed.

REFERENCES

1 Yates J R *Austr J Biol Sci* 21 361 (1968)
2 Protopapa E E, Tsigonia-Primikiriou A, Stavrianeas N G Effects of proteolytic enzymes papain, chymotrypsin and trypsin on the guinea pig skin with special reference to the hair follicle *Epitheor Klin Farmakol Farmakokinet Int Ed* 8 84-89 (1994)
3 Gaissert H, Protopapa E E et al Transgenic mice carrying the regulatory region of the human papilloma virus type 11 (HPV11). Their use in studying the effect of proteolytic enzymes on mouse skin hair follicles 35 *Wissenschaftliche Tagung der Gesellschaft für Versuchs-tierkunde Jena*, 1997
4 Gaissert H, Gissman L et al Regulation of HPV11 gene expression in transgenic mice, in *Proceedings of the sixth FELASA symposium*, O'Donoghue P N (ed) pp 54-55, The Royal Society of Medicine Press, London 1997
5 Unna P G Beiträge zur Histologie und Entwicklungs-geschichte der menschlichen Oberhaut und ihrer An-hängegebilde *Arch Mikroskop Anat Entwicklungsmech* 2 665-741 (1876)
6 Cotsarelis G, Sun T-T, Lavker R M Label-retaining cells reside in the bulge area of pilosebaceous unit: Implications for follicular stem cells, hair cycle and skin carcinogenesis *Cell* 61 1329-1337 (1990)
7 Avramiotis S, Xenakis A, Lianos P Lecithin w/o microemulsions as a host for trypsin. Enzyme activity and luminescence decay studies *Progr Colloid Polym Sci* 100 286-289 (1996)
8 Avramiotis S, Lianos P, Xenakis A Trypsin in lecithin based w/o Microemulsions. Fluorescence and enzyme activ-ity studies *Biocatal Biotransform* 14 299-316 (1997)